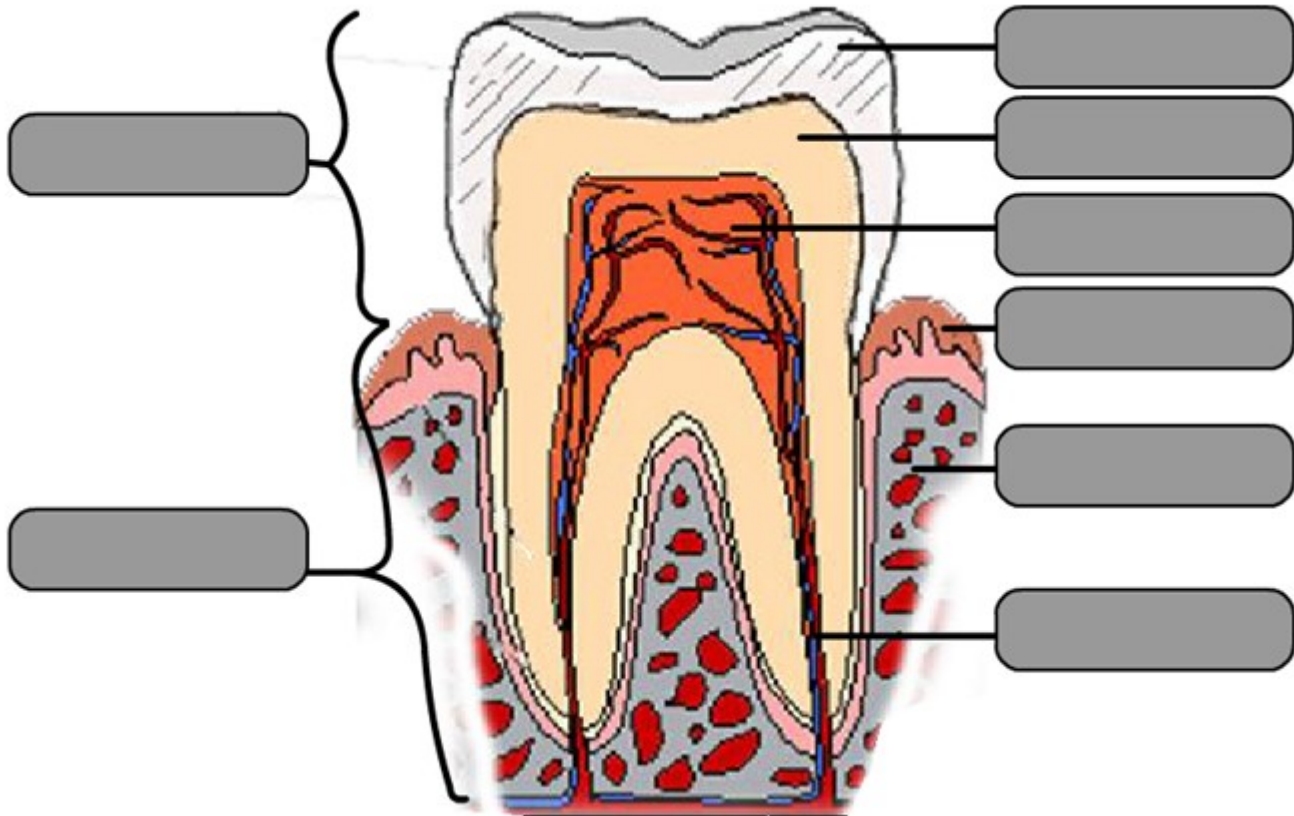


Use the information in the glossary to label the tooth structure:



Glossary

Crown: visible part of the tooth above your gum covered by enamel.

Dentine: hard tissue under the enamel of the tooth.

Enamel: the hard shiny outer surface of the tooth.

Gums: the firm flesh that surrounds the roots of the teeth.

Jaw bone: provides a solid base for the root to attach to the body.

Pulp: soft, spongy tissue in the centre of the tooth containing blood vessels and nerves.

Root: the part of your tooth in your gums that connects the tooth to the jaw.

Root canal: the nerve channel connecting the pulp chamber with the nervous system.